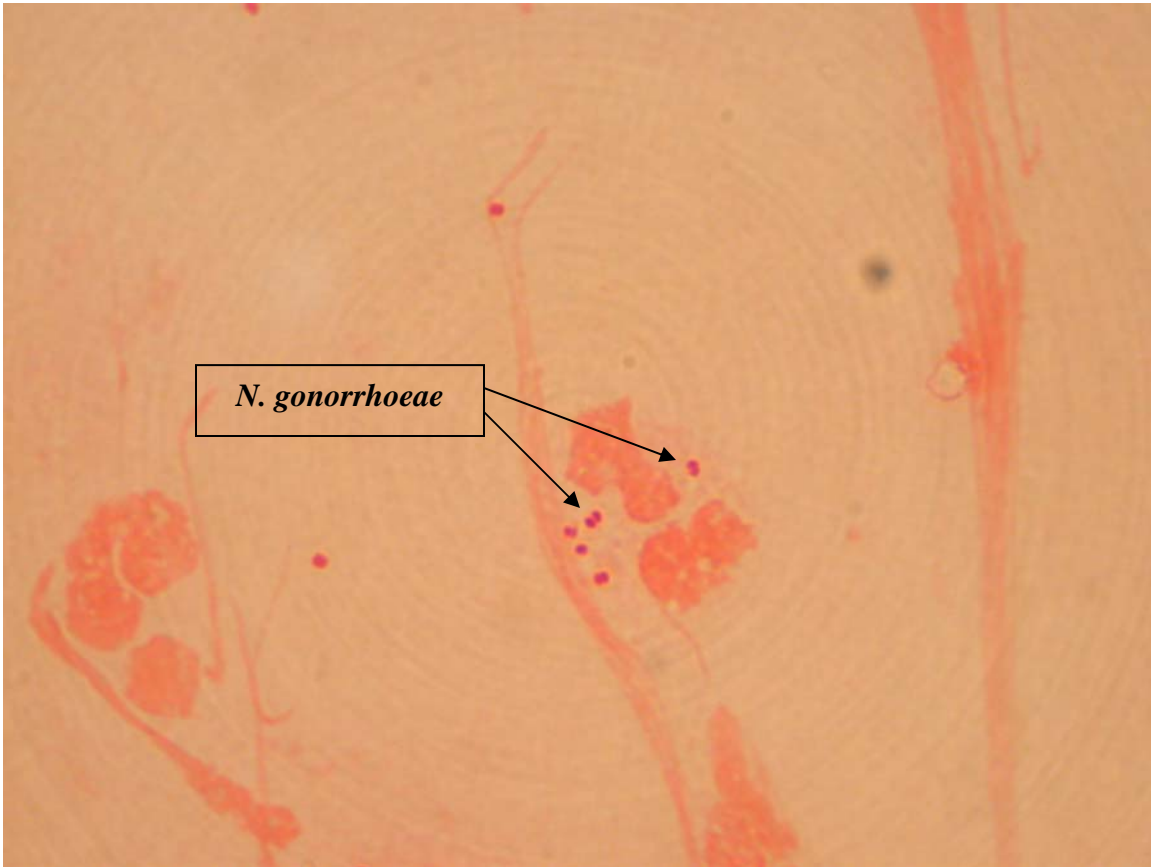


*Neisseria gonorrhoeae*



*Neisseria gonorrhoeae* – The causative agent of gonorrhea. This is a smear of pus taken from a lesion. Look for kidney-shaped pairs of cocci. The cells are flattened where they are adjacent. Notice that the indicated diplococci are also slightly out of focus.